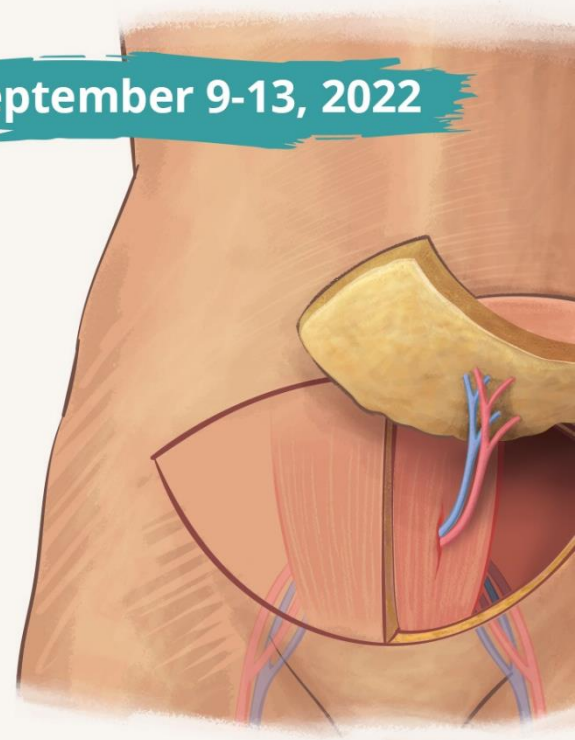


International Perforator Flap Dissection Course

September 9-13, 2022



Book of abstracts

Masaryk University Press
Brno 2022

International Perforator Flap Dissection Course

Two days dissection & two days of lectures, live surgeries and workshop on preoperative diagnostic.

www.dissectioncourse.org



CC BY-NC-SA 4.0 Creative Commons Attribution-NonCommercial-ShareAlike 4.0

© 2022 Masaryk University

ISBN 978-80-280-0109-4

Dear colleagues, dear friends,

It is my great pleasure and honour to invite you to the International Perforator Flap Dissection Course which will take place in Brno, Czech Republic, September 9-13, 2022.

This course has been designed to address the needs of the residents in plastic surgery wishing to learn flap dissection as well as more experienced plastic surgeons who wish to extend their repertoire of flap surgery.

The course will be held at the University Centre for Surgical Anatomy using fresh-frozen cadaver specimens enhanced by an advanced technique of coloured silicone vascular injections emphasizing the vascular anatomy of the flaps and facilitating the dissection.

A hands-on approach will be used with no more than two participants per cadaver specimen. All practical aspects of the course will take place in the anatomical laboratory. A multimedia approach will be used, and we recommend that registrants bring their own scrubs and loops. All other instrumentations will be supplied.

We wish you would accept our invitation and come to Brno to improve your microsurgical skills, meet new friends and explore the beautiful region of South Moravia.

We will be very pleased to welcome you at the International Perforator Flap Dissection Course in Brno.

Libor STREIT

Course Chairman

Department of Plastic and Aesthetic Surgery,
St. Anne's University Hospital Brno and Faculty of Medicine,
Masaryk University, Brno, Czech Republic

Place of venue

Saturday, September 10 & Sunday, September 11

University Centre for Surgical Anatomy, Masaryk University Faculty of Medicine
Kamenice 5, 625 00 Bohunice, Brno

Monday, September 12

Hotel International Husova 200 / 16, 602 00, Brno

Tuesday, September 13

The Simulation Centre of the Faculty of Medicine of Masaryk University
Kamenice 3, 625 00 Bohunice, Brno & St. Anne's University Hospital Brno

International Faculty

Joon Pio HONG (KOR)
Geoffrey G. HALLOCK (USA)
Jaume MASIA (ES)
Emanuele CIGNA (ITA)

Local Faculty

Libor STREIT
Course Chairman

Adam BAJUS
Zdenek DVORAK
Marek JOUKAL
Tomas KEMPNY
Tomas KUBEK
Adam NOVAK
Jiri VESELY

Organizing Committee

Andrej BERKES
Martin KUBAT
Jan MENOUSEK
Ondrej SEDIVY
Karolina SVOBODOVA

Course secretary

Masaryk University, Kamenice 753/5, 625 00 Brno, Czech Republic



CONTENT

Program	str. 5
Surgical Treatment of Oral Tumors with Primary Free Flap Reconstruction Inka TRESKOVA (CZ), L. Hauera, P. Andrlé, P. Posta, J. Podesvova	str. 10
The Use of 3D Facial Scanning in Objectifying the Results of Nasal Reconstruction Zdeněk DVOŘÁK (CZ), M. Kubát, F. Frait, T. Kubek	str. 10
Long-term Survival in Patients with Head and Neck Reconstruction after Radical Oncological Resection Jiří VESELÝ, J. Hložek, J. Krejčí, P. Smilek, I. Stupka, Z. Dvořák	str. 11
Double Cross-Face Nerve Grafting with Masseteric-Facial Nerve Coaptation and with Fascia Lata Suspensions: One-Stage Technique for Facial Reanimation Libor STREIT (CZ), C. Bayezid, N. Dubovska, J. Macek, A. Bajus, A. Berkes	str. 1
Multiple Free Flap Reconstructions on Upper and Lower Extremities Jiri VESELY (CZ), L. Drazan, J. Kucera, I. Stupka, V. Procházka	str. 12
Peroneal Artery Perforator Based Septocutaneous Free Flaps for Limb Reconstruction Martin MOLITOR (CZ), P. Christodoulou, P. Šuk, V. Lovětinská	str. 12
Long-term Results of Lower Leg Reconstruction Tomas KEMPNY (CZ), J. Holoubek, B. Lipový, M. Knoz	str. 13
FRAFF - Long Term Results, Donor Site Morbidity, Tips and Tricks Tomas VOTRUBA (CZ), V. Mařík, P. Kurial	str. 13
Thoracodorsal Artery Perforator Flap: Our Experience in Soft Tissue Reconstruction Paciorek M. (CZ), Wladyslaw GAWEL, Špičák M., Havránek P., Bortlíček M., Pliska L.	str. 14
Ukrainian Experience in the Treatment of Mine and Explosive Injuries Strafun S., Strafun O., Mariia KOTOVA (UA), Yarova M.	str. 15
Series of Medial Femoral Condyle Free Flaps for Upper Extremity Reconstructions Petr VONDRA (CZ)	str. 20
4th Contralateral IMAP Breast-Sharing Flap for Immediate Breast Reconstruction Luca PATANĚ (ITA), N. Felici	str. 20
Double Deep Inferior Epigastric Artery with Inter-Arterial Anastomoses: A Case Report (On-line) Jake HINDMARCH (AU), Pappas C., Yeap I., Karagiannis P., Jhattu H., Stern H.	str. 21

HANDS-ON PERFORATOR FLAP DISSECTION COURSE

DEMONSTRATION OF FLAP DISSECTIONS BY EXPERTS AND SIMULTANEOUS ON TRAINING DISSECTIONS BY PARTICIPANTS

FRIDAY, SEPTEMBER 9 – Hotel International Brno (Husova 16, Brno)

- 18:00 – 21:00 Registration (Hotel International Brno)
19:00 – 21:00 Welcome Cocktail – Srdcovka Jalta (Dominikánské náměstí 656/2, Brno-město)

SATURDAY, SEPTEMBER 10 – University Centre for Surgical Anatomy (Masaryk University, Faculty of Medicine, Kamenice 3, Brno)

- 07:30 – 07:50 Bus Transfer from Hotel to University Centre for Surgical Anatomy
07:30 – 08:20 Registration
08:00 – 08:20 Introduction to the Anatomical Laboratory
08:20 – 08:30 **Course Opening**
Libor STREIT, Marek JOUKAL
08:30 – 09:30 **ALT Flap (also Super-Thin and Suprafascial)**
demonstration by Joon Pio HONG
09:30 – 10:15 **TUG and Segmental Gracilis Flaps**
demonstration by Libor STREIT
10:15 – 10:45 Coffee Break
10:45 – 11:15 **PAP Flap**
demonstration by Geoffrey HALLOCK
11:15 – 12:00 **Vascularized Bone Flaps – Fibula and Medial Femoral Condyle**
demonstration by Tomas KEMPNY
12:00 – 12:30 **MSAP Flap**
demonstration Geoffrey HALLOCK
12:30 – 13:30 Lunch
13:30 – 14:00 **Toe to Hand Transfer**
demonstration by Jiri VESELY
14:00 – 14:30 **PIAP Flap**
demonstration by Joon Pio HONG
14:30 – 15:00 **Radial Forearm Flap**
demonstration by Emanuele CIGNA
15:00 – 15:30 Coffee Break
15:30 – 16:00 **SGAP & Propeller Flap**
demonstration by Joon Pio HONG
16:00 – 16:30 **Keystone Flap**
demonstration by Geoffrey HALLOCK
16:30 – 17:00 **Medial Plantar Flap**
demonstration by Joon Pio HONG

LECTURES

INVITED LECTURES, FREE ABSTRACTS SESSIONS AND BEST CASE COMPETITION

MONDAY, SEPTEMBER 12 – Hotel International Brno (Husova 16, Brno)

- 07:00 – 08:15 Registration
- 08:15 – 08:20 **Opening Remarks**
Libor STREIT (CZ)
- 08:20 – 08:30 **Welcome Speech**
Joon Pio HONG (KOR)
- 08:30 – 09:40 **SESSION I: PERFORATOR FLAPS I**
Chairmen: **Emanuele CIGNA (ITA), Martin MOLITOR (CZ)**
- 08:30 – 09:00 **A History of Perforator Flaps & Anatomical Basis and Classification**
Geoffrey G. HALLOCK (USA)
- 09:00 – 09:20 **Preoperative Planning**
Jaume MASIA (ES)
- 09:20 – 09:40 **How to Make Perforator Surgery Faster and Saver**
Joon Pio HONG (KOR)
- 09:40 – 10:10 Coffee Break
- 10:10 – 11:30 **SESSION II: PERFORATOR FLAPS II**
Chairmen: **Joon Pio HONG (KOR), Tomas KUBEK (CZ)**
- 10:10 – 10:30 **Chimeric Flaps**
Geoffrey G. HALLOCK (USA)
- 10:30 – 11:00 **Breast: Strategy & Flap Selection**
Jaume MASIA (ES)
- 11:00 – 11:30 **Head and Neck: Strategy & Flap Selection**
Emanuele CIGNA (ITA)
- 11:30 – 12:30 **SESSION III: HEAD & NECK**
Chairmen: **Jaume MASIA (ES), Tomas KEMPNY (CZ)**
- 11:30 – 11:45 **Surgical Treatment of Oral Tumors with Primary Free Flap Reconstruction**
Inka TRESKOVA (CZ), L. Hauera, P. Andrlé, P. Posta, J. Podesvova
- 11:45 – 12:00 **The Use of 3D Facial Scanning in Objectifying the Results of Nasal Reconstruction**
Zdeněk DVOŘÁK (CZ), M. Kubát, F. Frait, T. Kubek
- 12:00 – 12:15 **Long-term Survival in Patients with Head and Neck Reconstruction after Radical Oncological Resection**
Jiří VESELÝ, J. Hložek, J. Krejčí, P. Smilek, I. Stupka, Z. Dvořák
- 12:15 – 12:30 **Double Cross-Face Nerve Grafting with Masseteric-Facial Nerve Coaptation and with Fascia Lata Suspensions: One-Stage Technique for Facial Reanimation**
Libor STREIT (CZ), C. Bayezid, N. Dubovska, J. Macek, A. Bajus, A. Berkes
- 12:30 – 13:30 Lunch

- 13:30 – 14:45 **SESSION IV – INVITED LOCAL LECTURES**
Chairmen: **Geoffrey G. HALLOCK (USA), Zdeněk DVOŘÁK (CZ)**
- 13:30 – 13:45 **Multiple Free Flap Reconstructions on Upper and Lower Extremities**
Jiri VESELY (CZ), L. Drazan, J. Kucera, I. Stupka, V. Procházka
- 13:45 – 14:00 **Peroneal Artery Perforator Based Septocutaneous Free Flaps for Limb Reconstruction**
Martin MOLITOR (CZ), P. Christodoulou, P. Šuk, V. Lovětinská
- 14:00 – 14:15 **Long-term Results of Lower Leg Reconstruction**
Tomas KEMPNY (CZ), J. Holoubek, B. Lipový, M. Knoz
- 14:15 – 14:30 **FRAFF - Long Term Results, Donor Site Morbidity, Tips and Tricks**
Tomas VOTRUBA (CZ), V. Mařík, P. Kurial
- 14:30 – 14:45 **Thoracodorsal Artery Perforator Flap: Our Experience in Soft Tissue Reconstruction**
M. Paciorek (CZ), Wladyslaw GAWEL, M. Špičák, P. Havránek, M. Bortlíček, L. Pliska
- 14:45 – 15:45 **SESSION V: UPPER & LOWER EXTREMITY RECONSTRUCTION**
Chairmen: **Jiri VESELY (CZ), Emanuele CIGNA (ITA)**
- 14:45 – 15:15 **Local Perforator Flaps for the Lower Extremity**
Geoffrey G. HALLOCK (USA)
- 15:15 – 15:45 **Lower Extremity Reconstruction: Strategy & Flap Selection**
Joon Pio HONG (KOR)
- 15:45 – 16:15 Coffee break
- 16:15 – 17:45 **SESSION VI: BEST CASE COMPETITION**
Chairmen: **Geoffrey G. HALLOCK, Jaime MASIA, Joon Pio HONG, Emanuele CIGNA**
- 16:15 – 16:30 **Ukrainian Experience in the Treatment of Mine and Explosive Injuries**
S. Strafun, O. Strafun, Mariia KOTOVA (UA), M. Yarova
- 16:30 – 16:45 **Series of Medial Femoral Condyle Free Flaps for Upper Extremity Reconstructions**
Petr VONDRA (CZ)
- 16:45 – 17:00 **4th Contralateral IMAP Breast-Sharing Flap for Immediate Breast Reconstruction**
Luca PATANÈ (ITA), N. Felici
- 17:00 – 17:15 **Double Deep Inferior Epigastric Artery with Inter-Arterial Anastomoses: A Case Report (On-line)**
Jake HINDMARCH (AU), C. Pappas, I. Yeap, P. Karagiannis, H. Jhattu, H. Stern
- 17:15 – 17:25 **Award Ceremony for the Best Case Competition & Lecture Day Closing**
Geoffrey G. HALLOCK, Jaime MASIA, Joon Pio HONG, Emanuele CIGNA
- 19:00 – 23:00 **COURSE PARTY - Hotel International (Husova 16, Brno)**

WORKSHOP ON PREOPERATIVE DIAGNOSTIC OF PERFORATOR FLAP

ANGIO-CT & COLOR DUPLEX SONOGRAPHY

& LIVE SURGERIES

LIVE-STREAMING OF SURGICAL PROCEDURE BY EXPERTS WITH REAL TIME COMMENTARY AND DISCUSSION

TUESDAY, SEPTEMBER 13:

The Simulation Centre of the Faculty of Medicine of Masaryk University - Kamenice 3, Brno & St. Anne's University Hospital Brno

07:30 - 08:00 **LIVE SURGERIES PART I: PERFORATOR MAPPING AND PREOPERATIVE FLAP PLANING (Propeller Flap, SCIP, DIEP + LNT)**

By: Geoffrey G. HALLOCK, Joon Pio HONG, Jaume MASIA

08:00 - 10:00 **WORKSHOP ON PREOPERATIVE DIAGNOSTIC OF PERFORATOR FLAP - PART 1 (ANGIO-CT & COLOR DUPLEX SONOGRAPHY)**

By: Geoffrey G. HALLOCK, Joon Pio HONG, Jaume MASIA, Adam BAJUS, Tomas KUBEK, Adam NOVAK & Libor STREIT

- TAP & LICAP Flap
- SCIP Flap
- DIEP Flap & Groin LNT
- ALT Flap (also Super-Thin and Suprafascial)

10:00 - 15:30 **LIVE SURGERIES PART II: SGAP, SCIP, DIEP + LNT**

By: Geoffrey G. HALLOCK, Joon Pio HONG, Jaume MASIA

Commentators: Emanuele CIGNA & Tomas KEMPNÝ

- LIVE-STREAMING OF SURGICAL PROCEDURE BY EXPERTS WITH REAL TIME COMMENTARY AND DISCUSSION
- ENHANCED BY LIVE COMMENTED VIDEO SURGERY
- CONTINUOUS COFFEE BREAK DURING SURGERY

15:30 - 17:30 **WORKSHOP ON PREOPERATIVE DIAGNOSTIC OF PERFORATOR FLAP - PART 2 (ANGIO-CT & COLOR DUPLEX SONOGRAPHY)**

By: Geoffrey G. HALLOCK, Jaume MASIA, Joon Pio HONG, Adam BAJUS, Tomas KUBEK, Adam NOVAK & Libor STREIT

- TAP & LICAP Flap
- SCIP Flap
- DIEP Flap & Groin LNT
- ALT Flap (also Super-Thin and Suprafascial)

17:30 – 17:35 Closing
Libor STREIT

SURGICAL TREATMENT OF ORAL TUMORS WITH PRIMARY FREE FLAP RECONSTRUCTION

*Treskova I., Hauer L., Andrlé P., Posta P., Podesvova J.
Department of Plastic Surgery, University Hospital in Pilsen*

Objectives

Tumors of the oral cavity represent 4% of all malignancies. Extensive tumors require interdisciplinary collaboration between maxillofacial surgeon, plastic surgeon and anesthesiologist while planning the resection and reconstruction.

Materials and Methods

We present a review of 57 patients who underwent resection surgery with immediate free flap reconstruction performed in University Hospital in Pilsen. Few interesting cases will be presented in the lecture.

Results

R0 resection was achieved in 86% of patients, success rate of reconstruction was 94%. Few interesting cases will be presented in the lecture.

Conclusions

Surgical treatment of oral malignancies is the only curative modality. Using free flaps expands the indication criteria of otherwise inoperable conditions.

THE USE OF 3D FACIAL SCANNING IN OBJECTIFYING THE RESULTS OF NASAL RECONSTRUCTION

Dvorak Z.^{1,2,3}, Kubat M.^{1,2}, Frait F.², Kubek T.⁴

¹*Department of Plastic and Aesthetic Surgery St. Anne's University Hospital, Brno, Czech Republic*

²*Medical Faculty of Masaryk University, Brno, Czech Republic*

³*Department of Surgical Oncology Masaryk Memorial Cancer Institute Žlutý kopec, Brno, Czech Republic*

Background

The goal of nasal reconstruction is to restore not only the function of the patient's nose, but also a sufficient aesthetic result of the reconstruction. The aesthetic outcome of the surgery is difficult to assess, but it is important for the patient not to be socially handicapped. Most studies on nasal reconstruction evaluate the results by questionnaire studies, subjective evaluation by an independent assessor or by anthropometric measurements. 3D Face ID technology on the new iPhone 12 smartphones is a new non-invasive fast method that allows scanning the shape of the nose, electronically archiving the obtained result and also allowing measurements on a virtual model. This is possible by professional scanners too, which have high accuracy and a partial automatic evaluation. These include the Vectra H2 3D facial scanner. The disadvantage of professional scanners is the high purchase price and greater robustness.

Material and methods

Patients who underwent complex nasal reconstruction for transmural defect, i.e. reconstruction of all missing 3 layers of the nose, between January 1, 2016 and January 1, 2020 were included. A total of 17 patients were included in the study, 12 males and 5 females. The patients underwent the classic anthropometric measurement of the nose according to Farkas using a sliding millimeter scale and an angle gauge. Nine vertical, nine horizontal measurements and five angles of the nose and face were evaluated. In addition to the classical measurements, data were also obtained by 3D scanning in the Face App and Face Maker applications designed for the iPhone. Patients also underwent professional facial scanning on a Vectra H2 scanner in collaboration with the Department of Operative Oncology at the Masaryk Cancer Institute. Individual anthropometric dimensions were measured on virtual models by the authors using Blender software. The data were exported to the statistical software Gretl and evaluated.

Results

The most accurate measurement and partial automatic evaluation of the anthropometric values of the nose is possible with the Vectra H2 3D scanner. Its measurement accuracy is within tenths of mm. The standard deviation of the measurements was 1.56. Mobile applications allowing facial scanning proved to be sufficiently accurate for indicative anthropometric measurements, their standard deviations (SD 1.85 and SD 1.95) were comparable. The conventional caliper measurement on the patient proved to be the least accurate. SD was 3.53. The measured variables according to Farkas were within the limits of natural values for the nose.

Conclusions

3D scanning provides a good virtual documentation of the achieved result of nasal reconstruction. It is a high quality objective tool that can be used to repeatedly go back and compare, even retrospectively, the various newly determined variables. 3D scanning is non-invasive, fast and does not burden the patient. Mobile phone apps have sufficient resolution for clinical practice, which greatly enhances the practical use of these new objective tools.

LONG-TERM SURVIVAL IN PATIENTS WITH HEAD AND NECK RECONSTRUCTION AFTER RADICAL ONCOLOGICAL RESECTION

Veselý J., Hložek J. Krejčí J., Smilek P., Stupka I., Dvořák Z.

Department of plastic and aesthetic surgery, St. Anne university hospital, Brno

Department of ENT surgery, St. Anne university hospital, Brno

According to our experience, there are good conditions for radical tumour resections in head region most likely thanks to sinuses and oral and nose cavity. We present some difficult cases of adenocarcinoma, mucoid carcinoma and spinocellular carcinoma after unsuccessful *oncological treatment and ENT surgery* followed by our successful radical resection with primary reconstruction. There are patients whose survival is 25 and 27 years.

DOUBLE CROSS-FACE NERVE GRAFTING WITH MASSETERIC-FACIAL NERVE COAPTATION AND WITH FASCIA LATA SUSPENSIONS: ONE-STAGE TECHNIQUE FOR FACIAL REANIMATION

Streit L., Bayezid C., Dubovska N., Macek J., Bajus A., Berkes A.

Department of Plastic and Aesthetic Surgery St. Anne`s University Hospital, Brno, Czech Republic

Medical Faculty of Masaryk Univesity, Brno, Czech Republic

Authors' affiliation

Department of Plastic and Aesthetic Surgery, St. Anne's University Hospital Brno and Faculty of Medicine, Masaryk University, Brno, Czech Republic

Objetives

Cross-facial nerve grafting (CFNG) for facial reanimation is the standard treatment for recent acquired unilateral facial palsy providing spontaneity. Time required for nerve regeneration and the loss of axons when using nerve grafts are the limitations. Masseteric nerve (MN) has been described for babysitter procedure as well as for direct facial nerve cooptation as a potent neurotizer enabling early neurotization. The aim of this paper is to introduce a surgical approach for single-stage facial reanimation with double CFNG and ipsilateral masseteric-facial nerve coaptation together with the fascia lata suspensions (FLS).

Materials and Methods

Between October 2019 and August 2011, 5 patients, mean age 49.6 years [range, 35–58 years] affected by complete unilateral facial paralysis underwent single-staged facial reanimation. Ipsilateral MN was coaptated to the dominant distal zygomatic branch; contralateral distal zygomatic and buccal branches were coaptated to the another zygomatic and upper buccal branches via two CFNGs. Static

component consisted of nasolabial fold, nasal ala and lower eyelid FLS. For preoperative and postoperative assessments, we combined the clinician-based grading system (eFACE score) with the Facial Palsy Disability Questionnaire (FPD-Q) to gather the physician and patient perspectives together.

Results

In all the patients, facial symmetry at rest and lagophthalmos of the lower eyelid were enhanced immediately. Voluntary smile when biting down was observed within 4-5 months and spontaneous smile was restored within 8-10 months postoperatively. Preoperatively, the mean Smile Score (eFACE) was 44.8 % [range, 38.0-49.0 %] and the mean FPD-Q score was 42.7 % [range, 24.0-55.2 %]. In mean 14 [range, 4-22] months follow-up, the mean Smile Score was 77.2 % [range, 72.0-81.0 %] and the mean FPD-Q score was 60.9% [range, 41.0-75.0 %]. None of our patients experienced a major complication.

Conclusions

Double CFNG with masseteric-facial nerve coaptation and with FLS is a new reliable single-stage technique for facial reanimation. Restoration of static functions occurs immediately after surgery, followed by a gradual smile recovery.

MULTIPLE FREE FLAP RECONSTRUCTIONS ON UPPER AND LOWER EXTREMITIES

Veselý J., Dražan L, Kučera J., Stupka. I., Procházka V.

Department Plastic and Aesthetic Surgery , St. Anne´s University hospital Brno

Institute ofTraumatology , Ponávka 10, Brno

Multiple free flap reconstructions were used for severe extremity damages as secondary reconstructions in some of our patients. There were 2 similar cases of 3 free flaps reconstruction in one-stage surgery performed simultaneously by 2 teams. Due to flexor and extensor loss in the forearm, there were always used 2 gracilis muscles as motor units and the pre-expanded parascapular flaps to cover the reconstructed forearm. Vein grafts were used in all pedicles of 3 flaps used for reconstruction. Hand reconstructions by using 2 toes were performed in several post-traumatic conditions as well as in patients with congenital hand deformities. There were also 2 cases of free fibula flaps to reconstruct tibia and free latissimus dorsi flap to replace soft tissue above the reconstructed tibia. In both cases were used saphenous grafts for artery and vein defects between fibular pedicle and popliteal vessels and pedicle of latissimus dorsi were sutured end-to-side to those grafts. There were also 2 difficult cases showing functional reconstruction of upper or lower extremity with acute and delayed free flaps and secondary free flaps reconstruction to restore the function.

PERONEAL ARTERY PERFORATOR BASED SEPTOCUTANEOUS FREE FLAPS FOR LIMB RECONSTRUCTION

Molitor M., Christodoulou P., Šuk P., Lovětinská V.

Department of Plastic Surgery, University Hospital Na Bulovce, Prague

Perforator flaps provide a wide range of selection possibilities for reconstructive surgeons. There are over 350 perforators in the human body with various aesthetic properties both in the harvesting site and the replanting visual outcome.

Perforator flaps also provide a significant advantage in minimisation of donor site morbidity. This is particularly true when the harvested flap is only taken with its perforator sub-artery and the main artery is saved. This however generally requires the use of time consuming and tedious vascular microsurgery in the reconstruction.

In our presentation we will discuss two instances of peroneal artery perforator based septocutaneous free flaps used in leg reconstructive surgery. The first case involved the primary reconstruction of an ankle defect after a traffic accident. The second case was a secondary reconstruction of a scar contracture after a primary big toe replantation.

LONG TERM RESULTS OF LOWER LEG RECONSTRUCTION

Kempny T.^{1,2} Holoubek J.^{2,3} Lipovy B.^{2,3} Knoz M.^{3,4}

¹ *Medicent Clinic, Ostrava, Czech Republic*

² *Department of Burns and Reconstructive Surgery University Hospital Brno, Brno, Czech Republic*

³ *Faculty of Medicine, Masaryk University Brno, Czech Republic*

⁴ *Clinic of plastic and esthetic surgery, St. Anne's University Hospital, Brno, Czech Republic*

Topic of Interest

Authors presents long term series of lower extremities reconstruction after extensive devastating injury.

Objectives

Between years 1997 and 2015 were at the University hospital Ostrava, Tomas Bata hospital Zlín and University hospital Brno in Czech Republik, and at BHB Salzburg and at Klinikum Wels in Austria more than 200 replantations and over 1100 free flap surgeries performed.

Authors present possibilities of difficult lower extremities reconstruction after extensive devastating injury as an illustration of high level reconstructive surgery technique combining replantation with free flap reconstructive microsurgery concept.

Materials and Methods

New free flap techniques in autologous tissue transfer, minimalization of flap harvest defects and optimisation of aesthetic results are in a case of billateral devastating loss injury challenge for reconstructive microsurgeon to reach optimal result. Authors respond to nowadays demands in modern surgical practise, where the best result means to restore the function of harmed extremities and to improve patients live quality.

Results

Microsurgical concept of lower leg reconstruction proved to be safe and extremity saving rocedure in a case of devastating loss injury.

Conclusions

In our patients we rescuet with the damaged parts of the body from one leg function of the other leg using different microsurgical procedures. Even succesfully replanted part of the bodies were re-used like an second free flap to prevent new harvested areas.

Key words

Microsurgery, lower leg reconstruction.

FRAFF - LONG TERM RESULTS, DONOR SITE MORBIDITY, TIPS AND TRICKS

Votruba T.^{1,2} Mařík V.² Kurial P.²

¹ *Department of Plastic and Aesthetic Surgery, St. Anne's University Hospital Brno and Faculty of Medicine, Masaryk University, Brno, Czech Republic*

² *Department of Plastic Surgery , Hospital in České Budějovice, Czech Republic*

Introduction

Free radial artery forearm flap (FRAFF) was first described in 1978 by Yang et al. It has been used ever since for reconstruction of various areas. Main drawback of this flap is the donor site morbidity with prolonged healing, hypersensitivity and unstable scar.

Matherials and methods

Examination donor site morbidity of eighty two patients, who underwent this procedure at one department, performed by three surgeons during 26 years.

Minor branch of the study was to objectify the possibility of sensitive reinervation of this flap in ten cases, where lateral antebrachial cutaneous nerve was sutured.

Results

If the flap is properly raised and donor site is properly closed, no major donor site morbidity occurs. Problems with donor site result from a faulty pre-operative examination or poor surgical technique. Lateral antebrachial cutaneous nerve suture had no impact on sensitivity reinnervation of flap in our study.

Discussion

Are there still indications for FRAFF in 21st century?

THORACODORSAL ARTERY PERFORATOR FLAP: OUR EXPERIENCE IN SOFT TISSUE RECONSTRUCTION

Paciorek M.^{1,2}, Gawel W.¹, Špičák M.¹, Havránek P.^{1,2}, Bortlíček M.^{1,2}, Pliska L.^{1,2}

¹ *Department of Plastic and Reconstructive Surgery and Surgery of the Hand, University Hospital Ostrava*

² *Department of Surgical Studies, Faculty of Medicine, University of Ostrava*

Introduction

The thoracodorsal artery perforator flap (TAP flap) proved to be one of the ideal perforator flaps. The aim is to show its possibilities of use in different indications (free/pedicled), the method of preoperative marking of the perforator and the method of flap harvest (patient position and flap orientation).

Materials and Methods

We have performed a total of seven TAP flaps - two free and five pedicled, over a period from September 2010 to February 2021 at a single centre. Our indications have been: reconstruction of axilla, upper extremity, breast and oral cavity.

Results

The average perforator length is about 6 cm and the pedicle length can be extended to 10-12 cm by including the thoracodorsal artery. In perforator position is inconsistency, however, the presence of a perforator is certain. We prefer method of flap harvesting in lateral decubitus position, This eliminates the need for a position change during the operation and allow two teams approach. The paddle can be oriented vertically or horizontally with donor site scars in inconspicuous locations. The size of the skin paddle can be up to 15x25cm. In pedicled fashion provides a good colour match for upper extremities, axilla and breast.

Conclusion

The versatility of TDAP has several advantages that make it a workhorse flap for most reconstructions requiring soft tissue cover. Further, in the case of preoperatively detected pulsatile perforator by Doppler USG, its harvesting is suitable even for beginners. Its use in chimerism with the underlying latissimus dorsi muscle provides reconstruction for coverage and volume replacement.

UKRAINIAN EXPERIENCE IN THE TREATMENT OF MINE AND EXPLOSIVE INJURIES

Strafun S., Strafun O., Kotova M., Yarova M.

The Institute of Traumatology and Orthopedics, (Ukraine)

Objectives

In connection with Russia's military aggression against Ukraine, at one moment the number of patients with mine-explosive polystructural injuries, including massive wounds, increased. Defects of some tissues cannot be closed initially. In this clinical case, we would like to present our experience of treating a patient with a massive gunshot shrapnel wound of the right shoulder joint with a gunshot multifragmentary fracture of the proximal epimetaphysis of the right humerus with a massive soft tissue defect of the front surface of the right shoulder joint. Damage to the brachial artery, median and musculocutaneous nerves at the level of the proximal third of the shoulder and shoulder joint on the right.

Materials and Methods

On the fourth day of the war, a patient with an blast injury and massive wound with huge defect of soft tissue was admitted to our hospital. Male, 52 years old, paramedic. The patient was transferred from another hospital. His external fixation device was unstable, the rods were passed through the wound. At the first stage, we reassembled the EX-fix, since the rods could be pulled out with the fingers. And then we installed a VAC system with a constant negative pressure in the system of 120 mm Hg. Treatment with negative pressure continued for two weeks, VAC was changed every three days. After cleaning the wound and reducing its area, the defect is replaced with a thoracodorsal flap. After 3 months, the patient returned to our hospital for further reconstruction. After further examination and CT scan, a fracture of the diaphysis of the humerus with a bone defect was found, but the head and distal end of the humerus are intact. In view of the preserved head of the humerus and the shoulder joint, we decided to shorten the humerus by about 4 centimeters, replace the defect with a bone autograft and perform fixation with the long PHILOS system.

Results

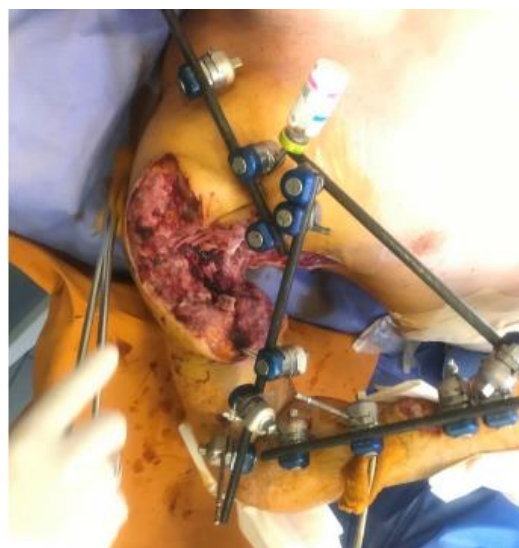After one month, the skin flap healed, the blood flow is compensated. The wound is completely closed. Thanks to this, we were able to fully move to the next stage and perform ORIF with shortening of the humerus and bone plastic. The next step is rehabilitation and restoration of movements in the elbow joint, as the elbow was fixed using an EX-fix for a long time. We expect fracture union in 6-8 weeks, given the quality of the bone tissue, and will be able to evaluate further results.

Conclusions

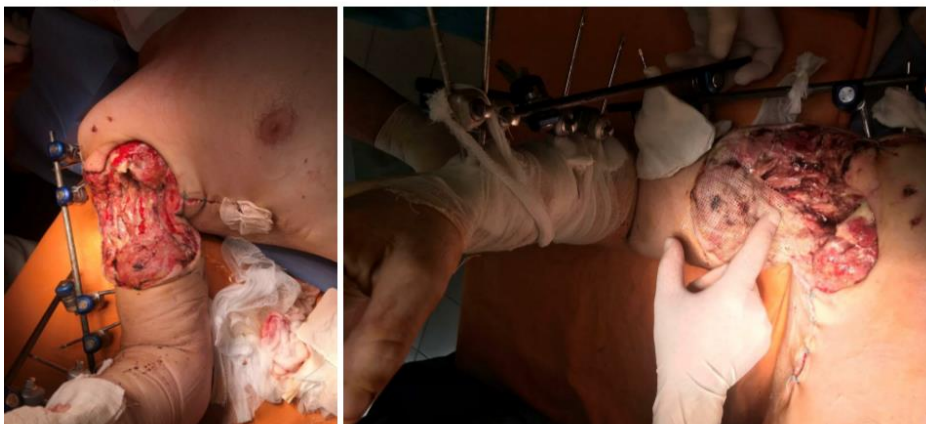Our experience with the thoracodorsal flap has been positive. In the aspect of mine-explosive wounds, our experience has shown that there is no need to rush - the wound needs aggressive debridement, massive washing and observation. In the case of polystructural trauma, we determined that soft tissues are in the first place, after healing of which we can proceed to further reconstructions.

Male, 52 years old, paramedic.

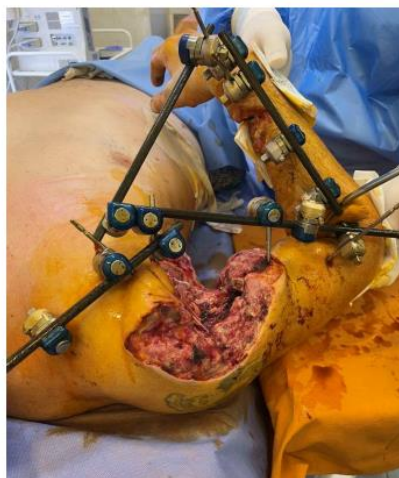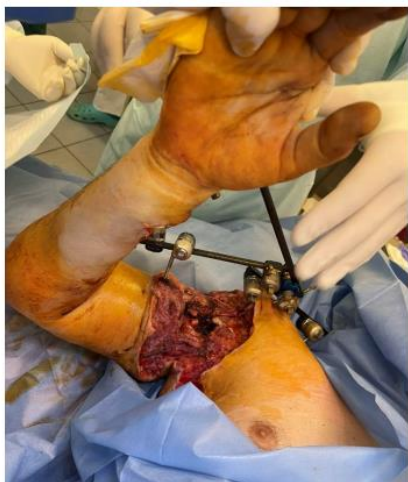- a massive gunshot shrapnel wound of the right shoulder joint with a gunshot multifragmentary fracture of the proximal epimetaphysis of the right humerus with a massive soft tissue defect of the front surface of the right shoulder joint. Damage to the brachial artery, median and musculocutaneous nerves at the level of the proximal third of the shoulder and shoulder joint on the right.



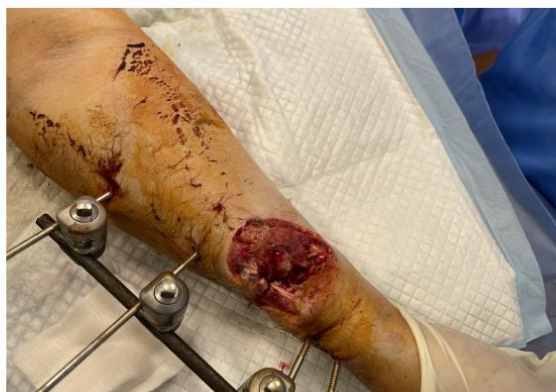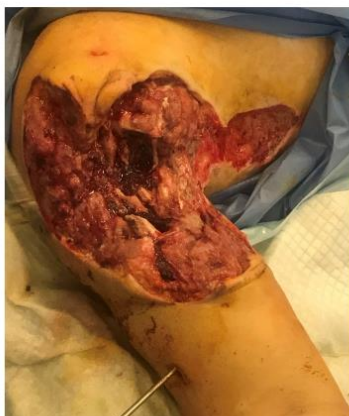Appearance of the wound



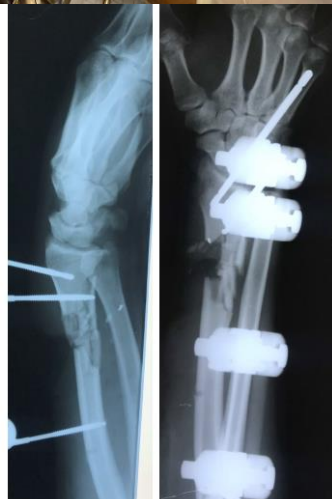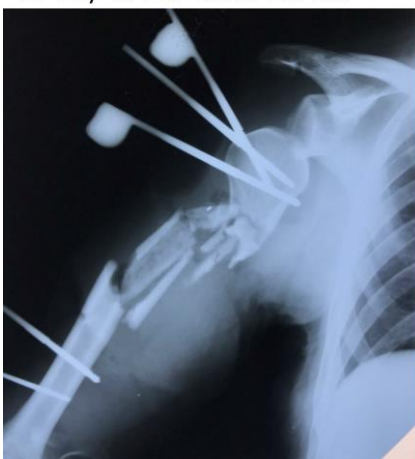At the first stage, we reassembled the EX-fix, since the rods could be pulled out with the fingers.



New Ex Fix

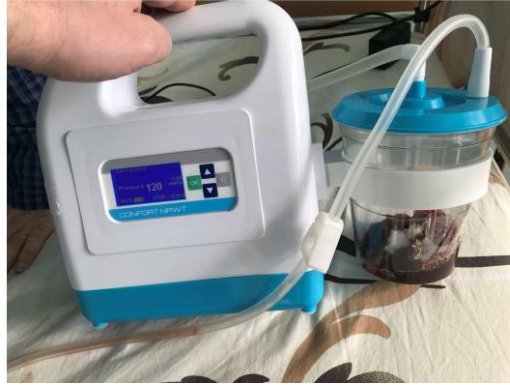

X-ray after new Ex-fix

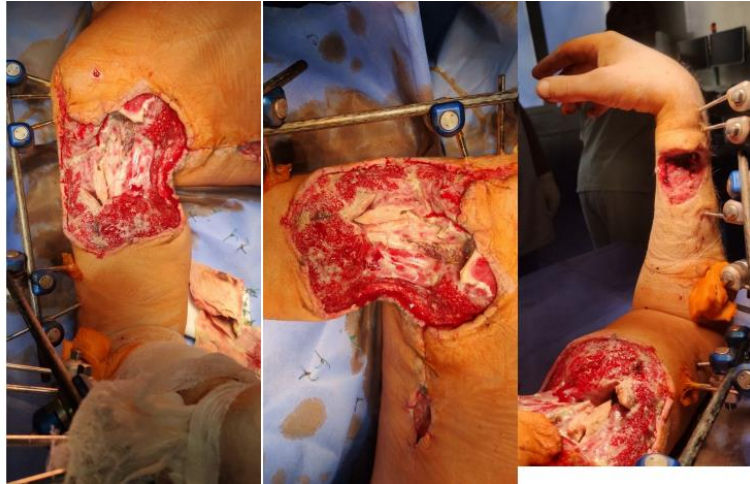




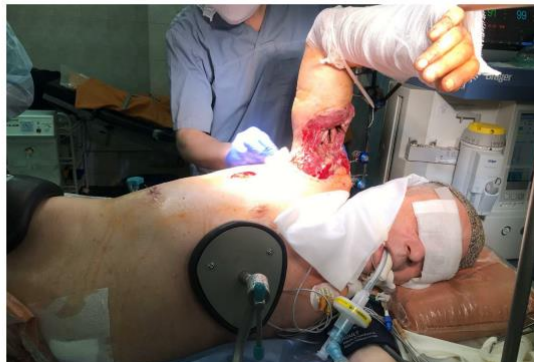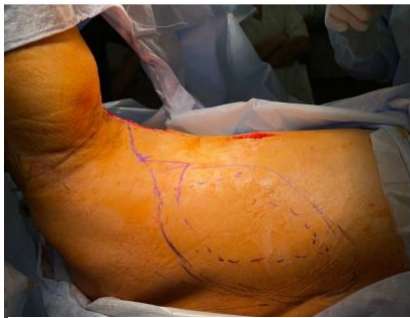And then we installed a VAC system with a constant negative pressure in the system of 120 mm Hg.



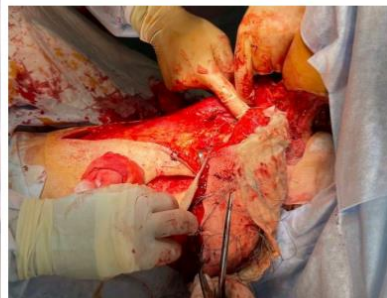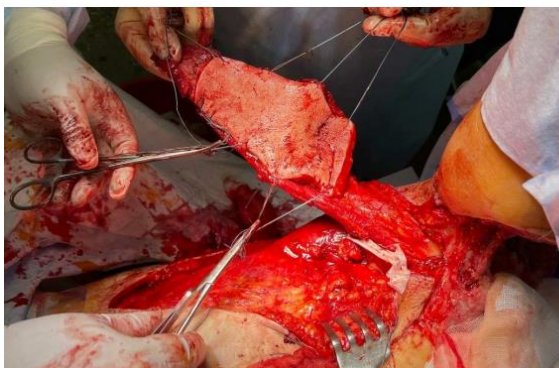After 1 week of VAC therapy



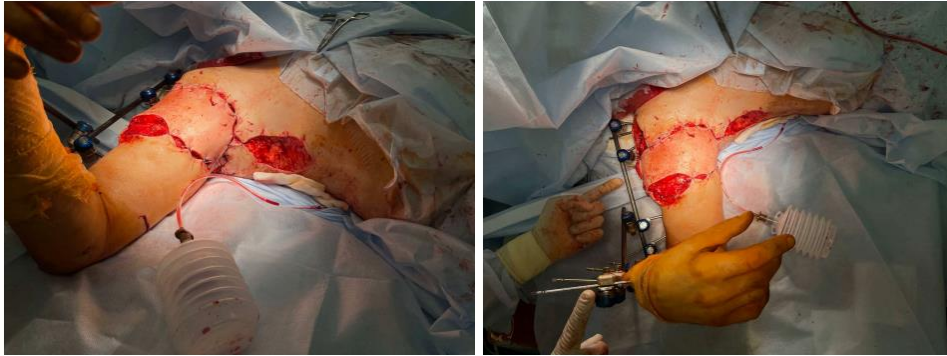Thoracodorsal flap



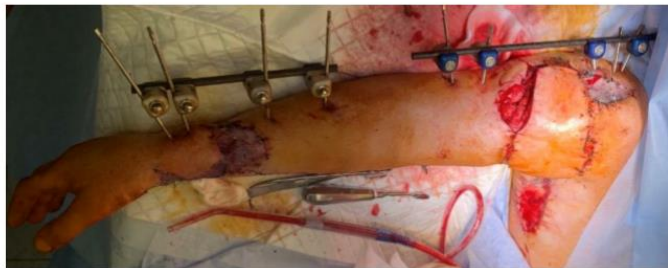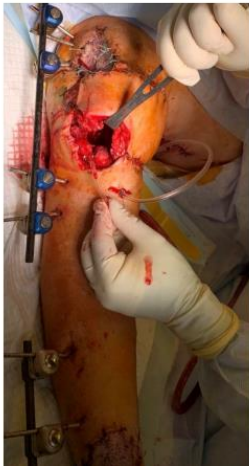Thoracodorsal flap



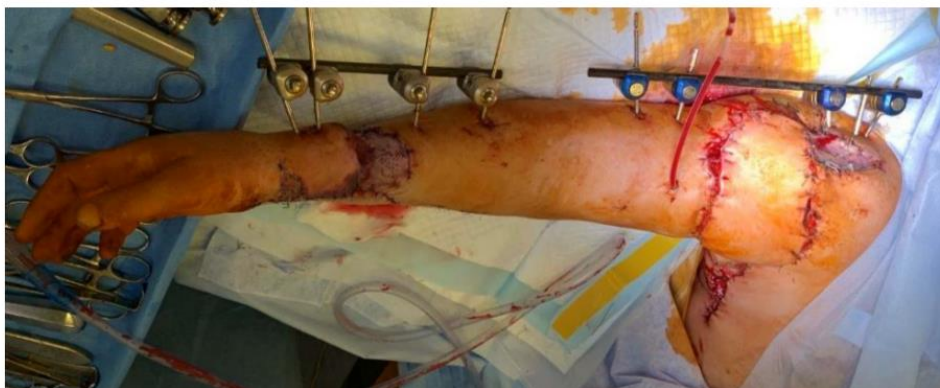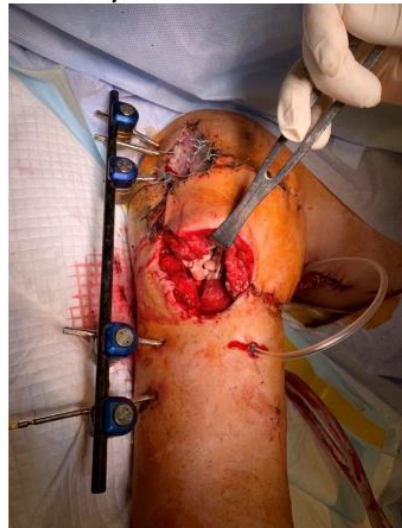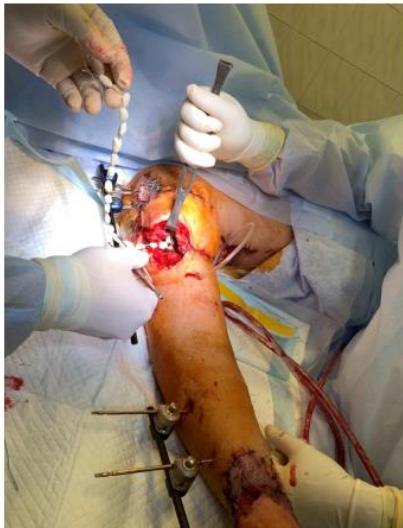Thoracodorsal flap



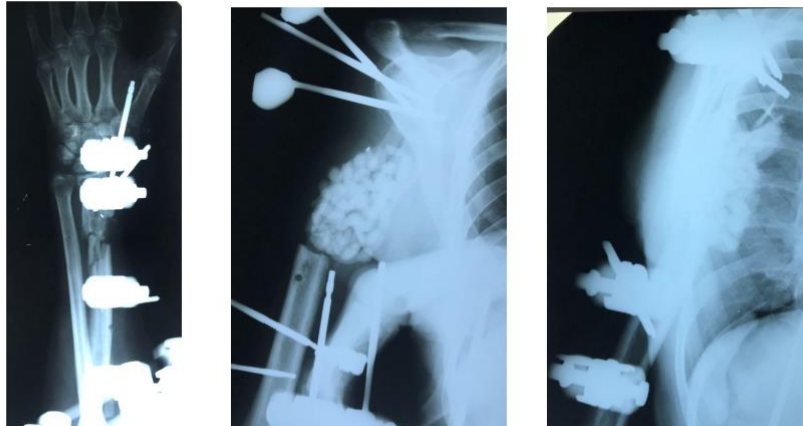
A week later, up to 50 ml of purulent exudate was released from under the flap. Therefore, necrectomy performed



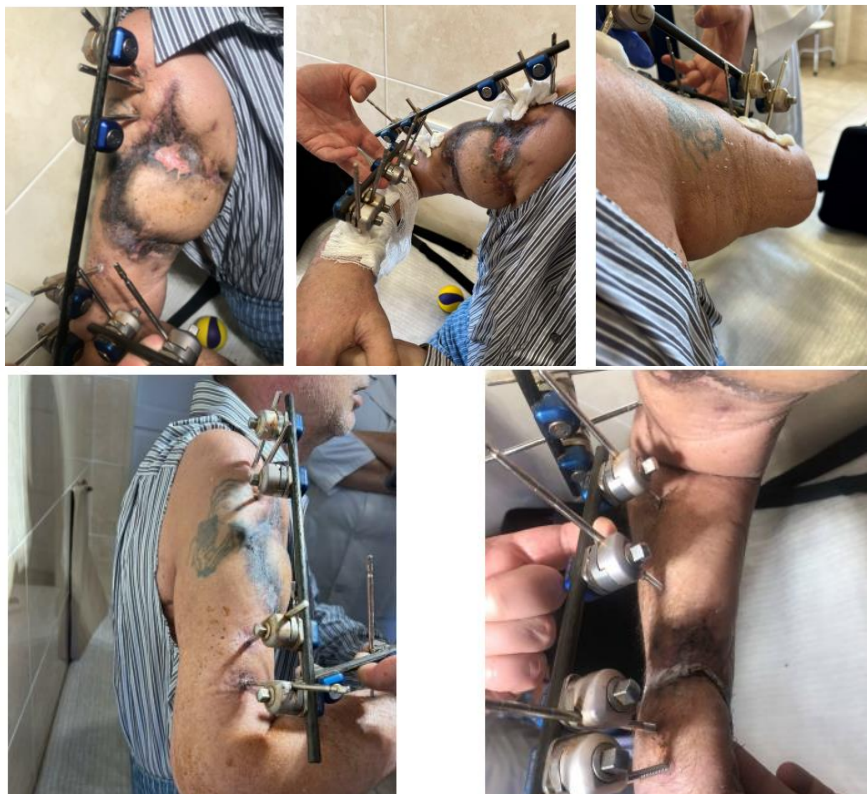And beads with an antibiotic were inserted into the cavity



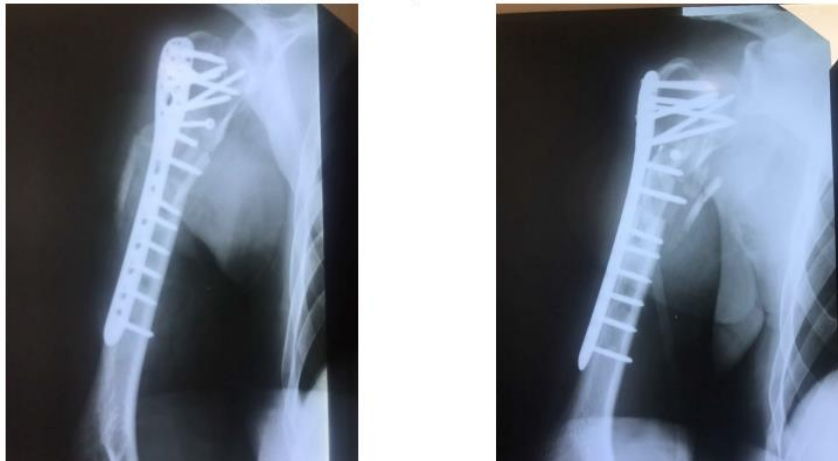X-ray after 3 months



Wound after 3 months



Performed surgery shortening the humerus by about 4 centimeters, replacing the defect with a bone autograft and fixation with the long PHILOS system.



SERIES OF MEDIAL FEMORAL CONDYLE FREE FLAPS FOR UPPER EXTREMITY RECONSTRUCTIONS

Vondra P.

Institute of Hand and Plastic Surgery Vysoké nad Jizerou

Objectives

Goal of the presentation is illustration of versatility of medial femoral condyle free flap (MFC) in upper extremity bone reconstructive surgery.

Materials and Methods

The MFC free flaps were used in number of cases including following diagnoses: scaphoid non-union, Kienböck disease, forearm bone non-union.

Results

All patients in this case report series healed relatively quickly and without requirement of any subsequent surgery.

Conclusions

MFC free flap is variable and effective reconstructive option for wide range of bone non-unions, segmental defects and avascular necroses.

4TH CONTRALATERAL IMAP BREAST-SHARING FLAP FOR IMMEDIATE BREAST RECONSTRUCTION

Patanè L. Felici N.

Azienda Ospedaliera San Camillo Forlanini, Unit of Reconstructive Surgery of the Limbs.

Objectives

The interest of using local perforator flaps for breast reconstruction is rising in the literature. Some recent reports highlighted the advantages of using the discarded breast tissue during breast symmetrisation of the contralateral reduced breast to reconstruct the mutilated breast in a one-stage approach. Some Authors reported their experience with breast reconstruction with the use of a contralateral IMAP free flap. Other authors used a split breast technique tunnelling the contralateral IMAP flap to reach the breast defect. We report the first case described in the literature of total left breast reconstruction following mastectomy with a flap based on a perforator of the contralateral internal mammary artery.

Materials and Methods

The donor site was selected on the base of the patient request to not have additional scars. The flap was sized 20x12 cm and was composed by breast parenchyma, subcutaneous tissue and the overlying skin: these tissues are usually discarded during breast reduction of the contralateral breast. The flap was harvested during mastectomy and no perforator mapping was performed preoperatively. During dissection, the largest perforator was selected (4th intercostal space) and dissected until adequate length was reached. Once the perforator was selected, indocyanine green fluorescence angiography was performed to assess flap vascularity. Once the mastectomy was completed, the flap was transposed to the defect and insetted through vycril 2-0 sutures positioned to the medial, upper and lateral border of the flap. A new fluoroscopy was performed once insetted with good outcome.

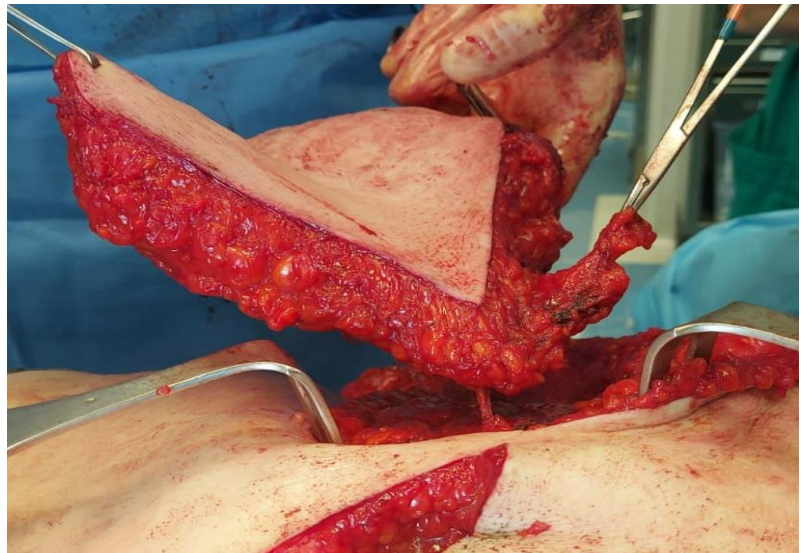
Results

At the first postoperative day, venous congestion was noted on the distal part of the flap, which later developed marginal skin and fat necrosis at 4 weeks. Closure of the defect was achieved with the excision of all the necrotic tissues and dressing with NPWT. At 8 months follow-up the patient was completely healed with a good aesthetic result.

Conclusions

The use of the contralateral breast for unilateral total breast reconstruction represents an additional useful technique for selected patients with a satisfying aesthetic result.

The flap pedicled on the 4th contralateral IMAP.



DOUBLE DEEP INFERIOR EPIGASTRIC ARTERY WITH INTER-ARTERIAL ANASTOMOSES: A CASE REPORT

Hindmarch J., Pappas Ch., Yeap I., Karagiannis P, Jhattu H., Stern H.

Objectives

We present the third case of a double deep inferior epigastric artery (DIEA), and to our knowledge, the first case of closely related double DIEA with significant arterio-arterial anastomoses, highlighting the importance of intra-operative awareness of potential vascular anatomical anomalies and the pitfalls of pre-operative pedicle localisation techniques.

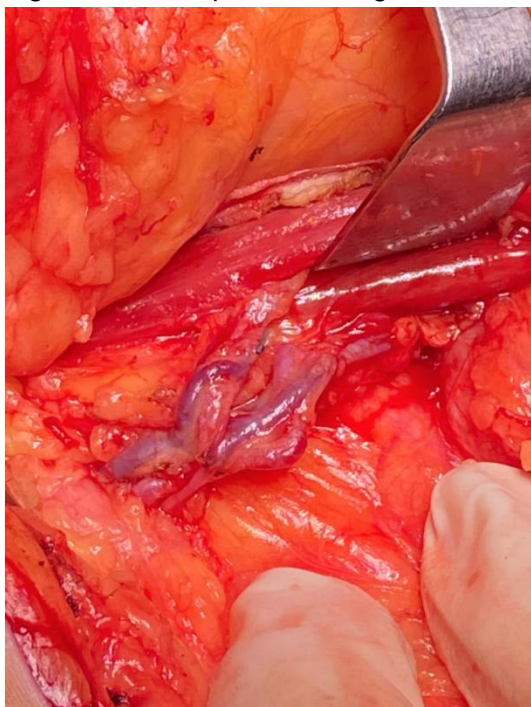
Materials and methods

A 63-year-old female presented to our facility with a left-sided breast malignancy previously managed by breast-conserving wide local excision and chemoradiotherapy. She was subsequently worked up for a completion left and prophylactic right mastectomy, with immediate bilateral free transverse rectus abdominus myocutaneous free flap reconstruction. Interestingly, routine pre-operative computed tomography angiography of the abdominal wall revealed minimal DIEA perforators, including a single right-sided infraumbilical perforator, and a single left-sided supraumbilical perforator. At operation, left-sided dissection revealed paired DIEAs, closely apposed with significant arterio-arterial anastomoses.

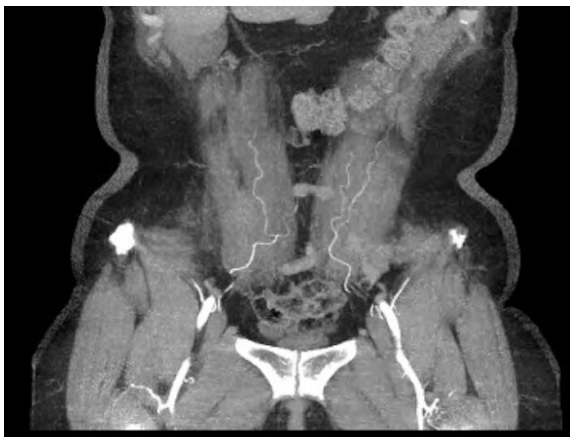

Figure 1. Pre-operative abdominal CT angiography, demonstrating a single right infraumbilical perforator, and a single left supraumbilical perforator. No duplicate DIEA is noted.

Figure 2. Intra-operative image of dissected subcutaneous tissue and rectus abdominus muscle. The double DIEA is visible in situ, with significant arterio-arterial anastomoses.



Results

The patient's postoperative course was unremarkable, and she was discharged soon after surgery with no evidence of flap necrosis or congestion. The donor site wound remained well perfused with minimal morbidity. Notably, a review of her pre-operative CT failed to demonstrate a clearly visible double DIEA.

Conclusion

We present the third case of a double deep inferior epigastric artery during autologous breast reconstruction and the first to display close apposition with significant arterio-arterial anastomoses. Our case highlights the importance of intra-operative awareness of anatomical variations in otherwise reliable vascular pedicles and the potential limitations of pre-operative localisation with CT angiography.

We dearly thank our partners for supporting this professional event

PARTNER



EXHIBITION



Authorized Distributor
GE Healthcare

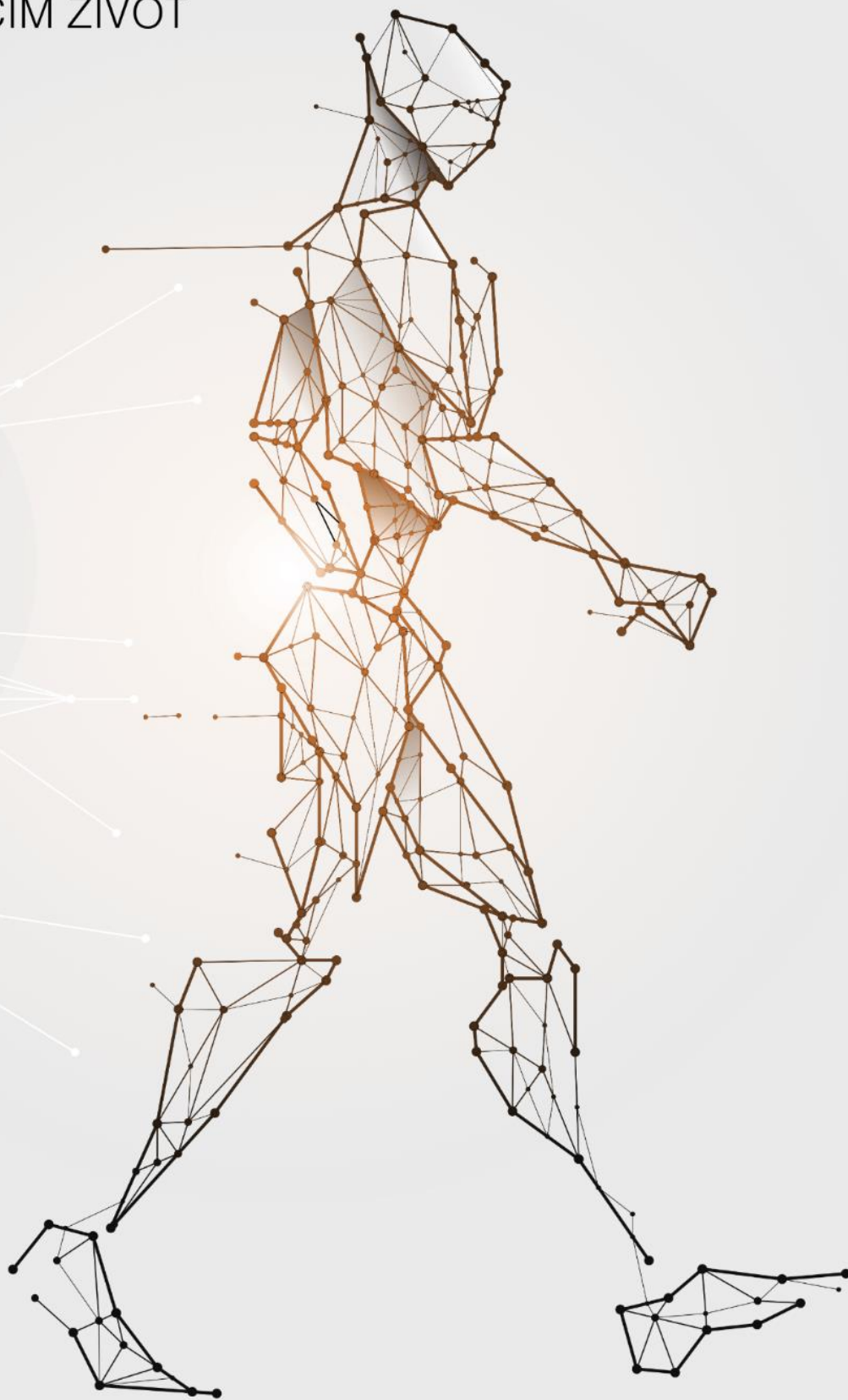

SUPPORT



VIVA a.s.

DÁVÁME INOVACÍM ŽIVOT




Hitaka
EUROPE

FLUOPTICS®

The Microsurgeon's Most Trusted Resource

+1 205-941-0111 • www.synovismicro.com • smca_orders@baxter.com



COUPLER and BIOVER CLAMP



GEM
Global Excellence in Microsurgery
Synovis MCA



International Perforator Flap Dissection Course

Book of abstracts

Edited by Šárka Martiníková

Published by Masaryk University, Žerotínovo nám. 617/9, 601 77 Brno, CZ

1st electronic edition, 2022

ISBN 978-80-280-0109-4